

ASSESSING DRUG RESPONSE WITH MULTIPLE MODALITIES USING ONCOQUANT



As part of the Dexus environment, OncoQuant* provides robust tools for routine oncology diagnosis, treatment follow up, and clinical trial management. OncoQuant integrates with existing IT infrastructure, including PACS and RIS, so clinicians can spend less time retrieving studies and preparing exams and more time reading and reviewing.

Isabelle Boulay, MD

Specialty: Medical Imaging in Gastro-intestinal (GI) and Urology Oncology.



According to Isabelle Boulay, MD, OncoQuant not only streamlines oncology data, but provides access to data in less time. Using OncoQuant, Dr. Boulay can save previous measurements and reload the results. With the PACS integration and pre-fetching, patients are preselected so she no longer waits to log in and search for the relevant exams. Images are also auto-registered when two or more studies are loaded.

In an analysis of the oncology workflow steps at St. Joseph Hospital (Paris, France), Dr. Boulay found that using OncoQuant with a PACS front-end integration reduced the time for oncology workflow. “OncoQuant is not only saving us 15% on reading time, but it definitely increases the repeatability of measurements over time,” she says. “In addition, OncoQuant frees up our oncologists helping give them more confidence in measurement tracking, diminishing the need to repeat the same measurements.”

Additionally, this becomes important when monitoring the reactions of specific drug treatments where CT doesn't provide enough information and MR brings the complementary information to conclude the assessment.

With OncoQuant, Dr. Boulay is able to establish a consistent and rapid diagnostic workflow across the CT and MR exams. Through this workflow, clinicians at St. Joseph Hospital can achieve:

- ▶ Quick comparison of follow-up exams from the baseline exam;
- ▶ Unlimited number of exam comparisons regardless of modality;
- ▶ Rigid registration across all exams (and all modalities) allowing evaluation at the same anatomical location in all reformat planes;
- ▶ Comparison of parametric data, diffusion, integration of different morphological criteria—RECIST 1.1 (standard), RECIST 1.0, and WHO—and any other “configured” or “user defined” criteria; and
- ▶ Monitoring of volume evolution even if not stated in the RECIST guidelines.

“Overall, OncoQuant provides a structured and repeatable workflow that helps improve the speed and efficiency of follow-up reviews and creates a method to initiate a standardized dialogue between several physicians in our network,” Dr. Boulay notes.

Summary

OncoQuant offers a set of tools that help to enable clinicians to quantify morphological and functional changes over time to help assess the success of treatment.

OncoQuant enables the portability and accessibility of information outside the department via the hospital network. Images and quantitative measurements can be exported in DICOM with a new layout designed for readability on PACS. OncoQuant will export statistical results in CSV format for further analysis in Excel or OpenOffice. The Mini Report feature facilitates the exporting of Baseline, Nadir, Prior, and Current data with one click.

For a research-driven workflow, the OncoQuant tools conform to RECIST (1.0, 1.1) and WHO with the capability to customize morphologic data and set specific rules for 1D, 2D, and 3D criterion types. OncoQuant also allows comparison between multiple modalities side by side in a single environment with no limit on the number of exams. **S**



“OncoQuant is not only saving us 15% on reading time, but it definitely increases the repeatability of measurements over time.”

Dr. Isabelle Boulay

The following case from Dr. Boulay illustrates how RECIST and MR imaging provide a full multi-modality assessment for oncologic patients.

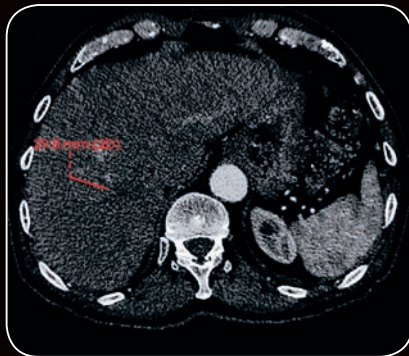


Figure 1. CT at early portal venous phase

Summary Table			
Stja MR SIGNA PHUSE			
	Jul 07 2011	Nov 03 2011	Nov 16 2011
1 - Finding 1	CT 3	CT 7	
User	Sr 4, Im 237	Sr 2, Im 287	
	2Dmax: 29.8 mm	2Dmax: 11.6 mm (-61%)	
3 - Finding 3		CT 7	MR M3D/LAVA
User		Sr 2, Im 233	ROI 4
		N/A	Sr 21, Im 37
			N/A
4 - Finding 4		CT 7	MR M3D/LAVA
User		Sr 2, Im 233	ROI 5
		N/A	Sr 21, Im 37
			N/A
ID - 5 Lesions	Sum: 29.8 mm	Sum: 11.6 mm (-61%)	No target defined.
	1 target lesion(s)	1 target lesion(s)	
		2 new lesion(s) (+2)	

Figure 2. OncoQuant Summary Table of results

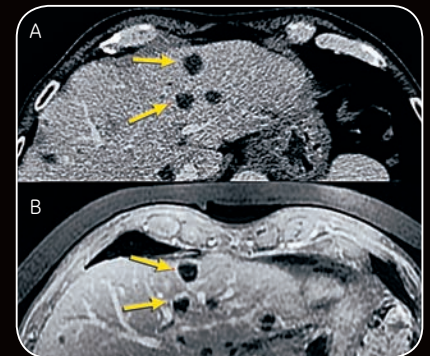


Figure 3. (A) CT follow up at portal phase; (B) 3D LAVA T1 (GRE) MR

Patient history

A 70-year-old patient diagnosed with rectal cancer and liver metastases. Initial staging was performed in July 2011 including CT chest/abdomen/pelvis exam and MR rectum + abdomen/pelvis exams. The first course of chemotherapy targeted the rectal and liver metastasis adenocarcinoma and the patient received follow up exams with CT and MR in November 2011.

Patient findings

Initial CT staging showed multiple metastases and cysts but also hypodense undefined lesions in the liver. A characterization MR exam was performed in July 2011 in order to clarify the status of the undefined lesions. Target lesions were identified

on the initial CT exam in July 2011 (Figure 1). In November 2011, most of the liver metastases decreased in size (Figure 2), while hypodense lesions appeared or increased on the CT exam (Figure 3A). The MR exam demonstrated a decrease in the size of the metastases and the hypodense undefined lesions found on the CT appeared to have a rim enhancement on T1 weighted images. Additionally, these lesions increased in size and were suspicious for metastasis (Figure 3B). A liver biopsy concluded that these lesions were mucinous metastases and confirmed the split evolution of the rectal cancer.

Discussion

The current guidelines used to assess tumor response during treatment, like RECIST, are based on anatomical

tumor size. When using specific drugs for chemotherapy, only some groups of cancer cells will respond while other types of cells might continue to grow. In this case, using only anatomical guidelines may not be sufficient to assess the response of the treatment and other imaging modalities can be used for the assessment.

For this patient, the anatomical tumor evolution based on CT exams alone did not bring the relevant information as new lesions can appear cyst-like. Evaluation of the patient's MR exams allowed us to hypothesize that this patient had two metastasis component cells: The adenocarcinoma appeared as solid metastasis that decreased in size under chemo and a mucinous cyst-like component appeared, which had no effective treatment.

Isabelle Boulay, MD, has spent over 14 years focusing on abdominal imaging in oncology, and reads/diagnoses everything from ultrasound, MR, and CT imaging. She completed her clinical fellowship at Hôpital Lariboisière in the GI radiology department where thereafter she began her career sharing her time between the Institute Marie Curie in Paris and Saint-Joseph in the first three years. Since then, she has been working full time as part of the Paris Saint-Joseph group.

The hospital group of Paris Saint-Joseph, administered by the Saint-Joseph Hospital Foundation, is a private nonprofit, participating with the national public hospital service.